Japan Journal of Medicine
2020; 3(2): 452-455 . doi: 10.31488/jjm.159

Research article

Tongue Inspection and Diagnosis: Past, Present, and Future

Yu-Chiang Hung[1*] MD. PhD, John Y. Chiang[2] PhD, Wen-Long Hu[1,3,4] MD. MS

1. Department of Chinese Medicine, Kaohsiung Chang Gung Memorial Hospital and Chang Gung University College of Medicine, Kaohsiung 833, Taiwan
2. Department of Computer Science & Engineering, National Sun Yat-sen University, Kaohsiung 424, Taiwan
3. Fooyin University College of Nursing, Kaohsiung 831, Taiwan
4. Kaohsiung Medical University College of Medicine, Kaohsiung 807, Taiwan

[*]**Corresponding author:** Yu-Chiang Hung, Kaohsiung Chang Gung Memorial Hospital, No. 123, Dapi Rd., Niaosng Dist, Kaohsiung City 83342, Taiwan.

Received: April 13, 2020; Accepted: May 05, 2020; Published: May 07, 2020

Abstract

A tongue can reflect the physiological and pathological condition of the body. We aim to review the past, present, and future aspects of the tongue inspection and diagnosis. Tongue inspection and diagnosis is a unique diagnostic method applied in TCM clinical practice for thousands of years. The normal tongue feature should be flexible, slightly moist and light red body with a thin white coating. Abnormal tongue features could reflect the pathological changes of certain diseases. Through observing the changes about the color, shape, fissure, red dot, ecchymosis, and the moisture in the tongue coating and body color, TCM physicians can find the internal organ disease and the severity of the disease. In the past, traditional tongue diagnosis depends on the doctor's subjective and qualitative observation. Now modernized tongue inspection and diagnosis for objectivity and quantification is necessary. Computerized automatic tongue diagnosis system for tongue diagnosis can aid TCM physicians in capturing quantitative features to improve reliability and consistency of diagnosis. AI-driven tongue diagnosis with mobile App may be developed for health diagnosis in the future.

Keywords: Tongue diagnosis, Automatic tongue diagnosis system, TCM

Introduction

The classical clinical examination in traditional Chinese medicine TCM includes four methods such as inquiry, inspection, auscultation and olfaction, and palpation. Based on the data collected by the four diagnostic methods, they can reveal where the disease is. Tongue diagnosis is a noninvasive observation method for thousands of years to understand the pathological changes of the body. According to the fundamental principles about " a part reflects the whole" and " abnormal external manifestations reflect internal organ diseases", abnormal tongue features could reflect the overall disharmony of the body.

Past: subjective and qualitative tongue inspection and diagnosis

In classical clinical practice of tongue diagnosis, TCM physicians observe tongue characteristics, such as the color, shape, fissure, red dot, ecchymosis, the coating and the moisture of a patient before deducing the ailment. The tongue can be divided into five areas. Various areas of the tongue reflect the disharmony state of the internal systems. According to the classical theory of Neijing, different abnormal parts of the tongue features can reflect the pathological changes of the corresponding internal organs. The tip of the tongue reflects the disease of the heart and lungs systems; the middle part of the tongue reflects the disease of the spleen and stomach systems; the root of the tongue reflects the disease of the kidney system; both sides of the tongue reflect the disease of the liver and gallbladder systems.

The normal tongue feature should be flexible, slightly moist and light red body with a thin white coating. Slight moist of the tongue indicates the intact body fluid. A normal body color should be light red. Pale, red, deep-red, purple, and blue can be abnormal color. Another normal tongue coating should be thin white. White, yellow, grey, and black can be abnormal coating. Tongue coating, including its biology (epithelial cells, blood cells, vascular endothelial cells, and bacteria) and its metabolites could provide useful information for disease diagnosis [1]. Abnormal tongue features can help TCM physicians to understand what is happening inside the patient's organ systems. Through observing the subjective and qualitative changes in the tongue coating and body color, TCM physicians can find the internal organ disease and the severity of the disease. For example, a pale tongue may be anemia or deficiency of blood; a dry and red tongue without coating may be sicca syndrome or deficiency of yin; a dry and red tongue with yellow coating may be inflammation or heat pattern; a stiff and not flexible tongue may be stroke or interior wind

lesion.

Traditional tongue diagnosis depends on the doctor's subjective and qualitative observation. However, diagnosis data collected through observation by physician is often biased by subjective judgment, limited by personal knowledge, experience, thinking patterns, diagnostic skills, environmental lighting and color perception/ interpretation. The lacking of precise or existing quantifiable standards is reflected on the facts that different practitioners may reach disparate judgments on the same tongue, while a practitioner may pass different diagnoses on the identical tongue examined at different time. It was reported that the mean intra-practitioner agreement reached 61%, while the inter-practitioner agreement was as low as 18.2% between 30 practitioners observing 10 tongue images [2]. Such inconsistency causes many people to question TCM as an unscientific, subjective method. In light of these aforementioned pitfalls, efforts on seeking the help of modern computer technology to assist TCM practitioners to establish reliable diagnoses by providing standardized procedures as well as objective, reliable, and quantified data. In order to be employed in clinical inspections, the equipment developed shall be able to cope with variable orientation and forces applied in extruding tongue and environmental lighting variations.

Present: objective and quantitative tongue inspection with modern tongue diagnosis equipment

Standalone system

With the advances of image capturing hardware and pattern recognition techniques, many computerized tongue image analysis systems were developed [3]. They differ in terms of the hardware components, e.g. camera, light source, color bar spatial arrangement, etc., color calibration, tongue segmentation, number and type of tongue features extracted. Another important factor that shall take into account is whether the efficacy of tongue diagnosis data derived from the specific equipment has been validated.

Take the automatic tongue diagnosis system (ATDS) developed by one of the author as an example [4], as shown in Fig. 1. The ATDS was developed to automatically perform tongue segmentation and feature extraction to assist the diagnosis of TCM practitioners. Moreover, the intra- and inter-observer agreements of the ATDS and TCM practitioners have been conducted[4]. The ATDS is shown to be more consistent with significantly higher intra-agreement than the TCM doctors (kappa value: 0.93 ± 0.06 versus 0.64 ± 0.13) with $P < 0.001$ (Student's t-test). Inter-agreements between the ATDS and TCM doctors, as well as among the TCM doctors are both moderate. Intra-rater agreement between direct subject tongue inspection and objective tongue image inspection was good (Cohen κ range 0.69-1.0) [5].

ATDS includes two major portions: image capturing and feature analysis. The consistency and stability of image capturing relies on brightness and color calibration to compensate for variation such as intensity and color temperature of light source and imaging hardware, for example, the type of cameras or their settings including resolution, shutter speed, aperture, and white balance. Analysis of tongue images proceeds in two steps, namely, isolation of the tongue region within an image and extraction of tongue features. The purpose of isolating the tongue region is to eliminate irrelevant lower facial portions and background surrounding the tongue, thereby facilitating feature identification and extraction. The extraction of tongue features employs criteria such as the aspect ratio, color composition, location, shape, and color distribution of the tongue, as well as the quantity of neighboring pixels. Distinguishing characteristics employed in tongue diagnosis are extracted, such as tongue color, tongue fissure, fur color, fur thickness, ecchymosis, tooth mark, red dot, saliva, and tongue shape, to further generate detailed information regarding length, area, moisture, and number of fissures, marks, and dots. ATDS has since been employed in deriving the tongue indices for breast cancer [6, 7], diabetes mellitus [8, 9], rheumatoid arthritis [10], and upper gastrointestinal disorders [11].

Objective and quantitative tongue inspection

With the combination of subjective clinical experience of the TCM physician and objective diagnostic instrument of the automatic tongue diagnosis system, TCM physician can truly find different tongue features among different diseases, as shown in Table 1.

Future tongue inspection and diagnosis

Mobile platform

There is a global rising demand for remote health monitoring to improve the quality of health services by providing the point-of-care (POC) diagnostics. The tongue diagnosis system has a trend of miniaturization by shifting to the mobile platform, e.g., smart phone, to take advantages of the advances in imaging sensor, image processing algorithms, communication and cloud computing. Coupled with noninvasive biomedical measurement provided by wearable sensing, e.g., smart watch, long-term personal health management can be reached by remote monitoring tongue features and vital bio-data. The bio-metric, including heart rate, menstrual cycle, ECG, blood glucose, weight, etc., collected by smart watch, is transmitted to the smart phone[27],

Figure 1. Modularized ATDS. Image acquisition and analysis are performed through a tablet.

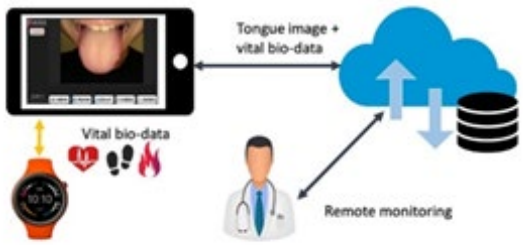

Figure 2. Tongue diagnosis, coupled with smart watch, to provide long-term health management by remote monitoring tongue features and vital biodata.

Table 1. Different features of the tongue inspection in different diseases

Authors	Disease	Abnormal Tongue Inspection
Pang W 2020[12]	Coronavirus	Mild to moderate: light red tongue and white coating; Severe: purple tongue and yellow coating
Wu TC 2020[13]	Gastroesophageal reflux disease	The amount of saliva and tongue fur in the spleen–stomach area
Liu M 2020[14]	Insomnia	Oral microbiome correlate with tongue coating
Ren Q 2020[15]	Coronary heart disease	Length of the crackle and number of ecchymosis
Hsu PC 2019[8]	Type II Diabetes mellitus	Covering area of yellow fur, thick fur, and bluish tongue
Cui J 2019[16]	Gastritis	Campylobacter concisus in tongue coating
Wu J 2018[17]	Gastric cancer	Streptococcus, abundance of Firmicutes and lower of Bacteroidetes in tongue coating
Lee TC 2016[18]	Metabolic syndrome	White coating
Lo LC 2015[6]	Breast cancer	Amount or covering area of tongue fur, thin tongue fur, red dot in the spleen- stomach area, and in the heart-lung area
RiYang L 2015[19]	membranous nephropathy	Tongue coating thickness is associated with lipid metabolism
Lee SH 2015[20]	Post-stroke depression	Purple tongue with yellow fur; old, soft, thin, enlarged, thorny, and cracked tongue
Liu X 2015[21]	Gastritis	H. pylori in tongue coating
Han s 2014[22]	Colorectal cancer	Thick tongue coating
Lo LC 2013[10]	Rheumatoid arthritis	Width, length, and count of sublingual vessels
Liang W 2013[23]	Post-menopausal osteoporosis	Decrease number of epithelial cells and bacteria in the red tongue with a thin coating
Zhao Y 2013[24]	Hepatitis B	Thick yellow coating or thick white coating
Wang HH 2012[25]	Peptic ulcer	Thin tongue fur, white color, sublingual veins with engorgement and blood stasis
Jiang M 2011[26]	Rheumatoid arthritis	Western therapy was be less effect for the patients with purple or red tongue body, or white tongue coating

as shown in Fig. 2. Along with the tongue image captured by the integrated phone camera, these bio-info is relayed to the cloud server for analysis and tracking. The person himself and designated doctor will be alerted if the health data fluctuate aberrantly or exceed preset upper/lower thresholds. Incorporating tongue diagnosis into the mobile platform will greatly increase the scope for wider application of tongue diagnosis in the upcoming future, including Western medicine.

AI-driven tongue diagnosis

There has been an explosion in researches employing artificial intelligence(AI) for medical image interpretation including organ and lesion segmentation, disease detection and classification, and assessment of response to treatment. Artificial intelligence in which algorithms can "learn" from data by identifying relevant patterns, using structured data sets to modify themselves in order to derive outputs. Automated segmentation, determining the boundaries of an organ or lesion, is crucial as an AI application for reducing the burden on doctors to perform segmentation manually. An AI-driven model to automatically segment tongue and extract relevant features with high degree of reliability therefore will find great clinical usefulness.

Artificial intelligence is a branch of computer science that encompasses machine learning (ML), representation learning, and deep learning (DL) [28]. With tongue diagnosis in mind, the author performed preliminary studies to establish a unified AI model using convolutional neural network (CNN) with Unet++ architecture [29] (Fig. 3) to segment the tongue images acquired both through stand-alone ATDS and mobile phone. The AI approach is highly tolerant of variations in the image forming process with much higher accuracy in tongue segmentation than the traditional counterpart. Using deep convolutional neural network for recognizing unhealthy tongue, the AI paradigm poses great potential for feature extraction and syndrome classification in the observation diagnosis [30].

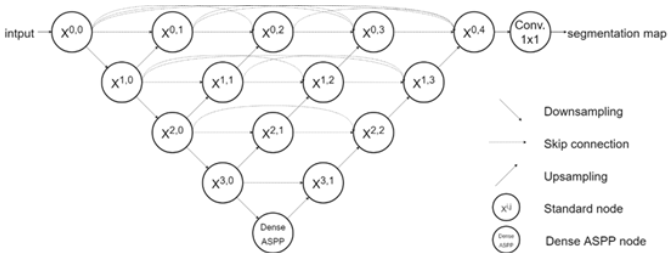

Figure 3. Schematic of AI model using convolutional neural network with Unet++ architecture

Conclusion

On the basis of TCM tongue diagnosis, clinical modernization of tongue diagnosis for objectivity and quantification is necessary. Computerized tongue diagnosis can aid TCM physicians in capturing quantitative features to improve reliability and consistency of diagnosis. AI-driven tongue diagnosis with mobile App may be developed for health diagnosis in the future.

Acknowledgement

This study was supported by the Chang Gung Medical Research Fund (CMRPG8H0691 & CMRPG8E0822).

References

1. Sun S, Wei H, Zhu R, et al. Biology of the Tongue Coating and Its Value in Disease Diagnosis.Complement Med Res. 2018;25(3):191-197.
2. Kim M, Cobbin D, Zaslawski C. Traditional Chinese medicine tongue inspection: an examination of the inter- and intrapractitioner reliability for specific tongue characteristics. J Altern Complement Med. 2008;14(5):527-36.
3. Tania MH, Lwin K, Hossain MA. Advances in automated tongue diagnosis techniques.Integr Med Res.2019; 8(1): 42–56.
4. Lo LC, Chen YF, Chen WJ, et al. The Study on the Agreement between Automatic Tongue Diagnosis System and Traditional Chinese Medicine Practitioners. Evid Based Complement Alternat Med. 2012;2012:505063.
5. Wang ZC, Zhang SP, Yuen PC, et al. Intra-Rater and Inter-Rater Reliability of Tongue Coating Diagnosis in Traditional Chinese Medicine Using Smartphones: Quasi-Delphi Study. JMIR Mhealth Uhealth. 2020;8(7):e16018.
6. Lo LC, Cheng TL, Chen YJ, et al. TCM tongue diagnosis index of early-stage breast cancer.Complement Ther Med. 2015;23(5):705-13.
7. Lo LC, Cheng TL, Chiang JY, et al. Breast Cancer Index - A Perspective on Tongue Diagnosis in Traditional Chinese Medicine. J Tradit Complement Med. 2013;3(3):194-203.
8. Hsu PC, Wu HK, Huang YC, et al. The tongue features associated with type 2 diabetes mellitus. Medicine (Baltimore). 2019;98 (19):e15567.
9. Hsu PC, Huang YC, Chiang JY, et al. The association between arterial stiffness and tongue manifestations of blood stasis in patients with type 2 diabetes.BMC Complement Altern Med. 2016;16(1):324.
10. Lo LC, Chen CY, Chiang JY, et al. Tongue diagnosis of traditional Chinese medicine for rheumatoid arthritis. Afr J Tradit Complement Altern Med. 2013 ;10(5):360-9.
11. Wu TC, Wu KL, Hu WL, et al. Tongue diagnosis indices for upper gastrointestinal disorders: Protocol for a cross-sectional, case-controlled observational study.Medicine (Baltimore). 2018;97(2):e9607.
12. Pang W, Zhang D, Zhang J, et al. Tongue features of patients with coronavirus disease 2019: a retrospective cross-sectional study. Integr Med Res. 2020;9(3):100493.
13. Wu TC, Lu CN, Hu WL, et al. Tongue diagnosis indices for gastroesophageal reflux disease: A cross-sectional, case-controlled observational study. Medicine (Baltimore). 2020;99(29):e20471.
14. Liu M, Wang X, Wu F, et al. Variations of Oral Microbiome in Chronic Insomnia Patients with Different Tongue Features. Am J Chin Med. 2020;48 (4):923-944.
15. Ren Q, Zhou XW, He MY, et al. A Quantitative Diagnostic Method for Phlegm and Blood Stasis Syndrome in Coronary Heart Disease Using Tongue, Face, and Pulse Indexes: An Exploratory Pilot Study.J Altern Complement Med. 2020;26(8):729-737.
16. Cui J, Cui H, Yang M, et al. Tongue coating microbiome as a potential biomarker for gastritis including precancerous cascade. Protein Cell. 2019 ;10(7):496-509.
17. Wu J, Xu S, Xiang C, et al. Tongue Coating Microbiota Community and Risk Effect on Gastric Cancer. J Cancer. 2018;9(21): 4039-4048.
18. Lee TC, Lo LC, Wu FC. Traditional Chinese Medicine for Metabolic Syndrome via TCM Pattern Differentiation: Tongue Diagnosis for Predictor. Evid Based Complement Alternat Med. 2016;2016:1971295.
19. RiYang L, HangYing Y, JunYan Q, et al. Association between tongue coating thickness and clinical characteristics among idiopathic membranous nephropathy patients. J Ethnopharmacol. 2015;171:125-30.
20. Lee SH, Niu T, Yang X, et al. Quantitative Investigation of Pulse and Tongue Features in Post-Stroke Depressive Patients and Healthy Volunteers: An Observational Pilot Study. Forsch Komplementmed. 2015;22 (5):292-7.
21. Liu X, Sun ZM, Liu YN, et al. The Metabonomic Studies of Tongue Coating in H. pylori Positive Chronic Gastritis Patients. Evid Based Complement Alternat Med. 2015;2015:804085.
22. Han S, Chen Y, Hu J, et al. Tongue images and tongue coating microbiome in patients with colorectal cancer. Microb Pathog. 2014:1-6.
23. Liang W, Li X, Li Y, et al. Tongue coating microbiome regulates the changes in tongue texture and coating in patients with post-menopausal osteoporosis of Gan-shen deficiency syndrome type. Int J Mol Med. 2013;32(5):1069-76.
24. Zhao Y, Gou XJ, Dai JY, et al. Differences in metabolites of different tongue coatings in patients with chronic hepatitis B. Evid Based Complement Alternat Med. 2013;2013: 204908.
25. Wang HH, Pan CH, Wu PP, et al. Alteration of the tongue manifestation reflects clinical outcomes of peptic ulcer disease.J Altern Complement Med. 2012;18(11):1038-44.
26. Jiang M, Zha Q, Lu C, et al. Association between tongue appearance in Traditional Chinese Medicine and effective response in treatment of rheumatoid arthritis.Complement Ther Med. 2011;19(3):115-21.
27. Kanawong R, Obafemi-Ajayi T, Liu D, et al. Tongue Image Analysis and Its Mobile App Development for Health Diagnosis. Adv Exp Med Biol. 2017; 1005:99-121.
28. Jiang F, Jiang Y, Zhi H, et al. Artificial intelligence in healthcare: past, present and future. Stroke Vasc Neurol. 2017;2(4):230-243.
29. Maas AL, Hannun AY, Ng AY. Rectifier nonlinearities improve neural network acoustic models. Proc icml. 2013;30:3.
30. Wang X, Liu J, Wu C et al. Artificial intelligence in tongue diagnosis: Using deep convolutional neural network for recognizing unhealthy tongue with tooth-mark. Comput Struct Biotechnol J. 2020;18:973-980.

To cite this article: Hung YC, Chiang JY, Hu WL. Tongue Inspection and Diagnosis: Past, Present, and Future. Japan Journal of Medicine. 2020; 3:2.